

# Balloon Dilation Atrial Septostomy and Potts Anastomosis for Severe Pulmonary Arterial Hypertension: Why, When, and How

Julio Sandoval, MD  
*Ignacio Chávez National Institute of  
Cardiology  
Mexico City, Mexico*

Tomás Pulido, MD  
*Ignacio Chávez National Institute of  
Cardiology  
Mexico City, Mexico*

Juan Pablo Sandoval, MD  
*Ignacio Chávez National Institute of  
Cardiology  
Mexico City, Mexico*

Nayeli Zayas, MD  
*Ignacio Chávez National Institute of  
Cardiology  
Mexico City, Mexico*

Jorge Gaspar, MD  
*Ignacio Chávez National Institute of  
Cardiology  
Mexico City, Mexico*

Despite advances in pharmacologic treatment, pulmonary arterial hypertension (PAH) remains a fatal disease. In recent years, surgical/interventional approaches including balloon dilation atrial septostomy and Potts anastomosis have been applied to improve the hemodynamic variables associated with right ventricular failure in the setting of PAH. These interventions may improve quality of life and prolong survival in this population. In this review, we will discuss the role of these 2 therapeutic alternatives in the management of PAH.

Without treatment, pulmonary arterial hypertension (PAH) is characterized by progressive elevation of pulmonary artery pressure, worsening right heart failure, and eventually death. Results from the National Institutes of Health Registry study in the United States<sup>1</sup> showed that patients with a cardiac index (CI)  $<2.0$  L/min/m<sup>2</sup>, and particularly those with mean right atrial pressure (mRAP)  $>20$  mm Hg, had poor expectancy for survival. These findings, consistent with those shown by other studies,<sup>2</sup> provided evidence that, indeed, survival in PAH depends on right ventricular (RV) function/dysfunction.

Currently, pharmacologic options for PAH are better; PAH-specific drugs

improve exercise endurance, quality of life, and survival of patients.<sup>3,4</sup> However, pharmacologic interventions are not always accessible and, most importantly, not all patients respond to treatment. Many patients will continue to deteriorate and will eventually be in need of alternative interventions such as atrial septostomy or Potts anastomosis. These surgical/interventional approaches were initially designed for patients born with congenital heart disease (CHD),<sup>5,6</sup> but in recent years have been applied to improve the hemodynamic variables associated with RV failure (RVF) in the setting of PAH. Here we review the role of these 2 nonpharmacological alternatives in the management of PAH.

## ATRIAL SEPTOSTOMY

### *Background and Rationale*

There is both clinical and experimental evidence suggesting that, in the setting of PAH, an interatrial right-to-left shunt may be of benefit. From a clinical standpoint, we know that PAH patients with a patent foramen ovale survive longer than those without one.<sup>7</sup> We also know that Eisenmenger patients with a comparable degree of pulmonary hypertension (PH) survive longer and do not develop severe RV dysfunction when compared to patients with PAH, reflecting better RV performance in Eisenmenger's physiology.<sup>8,9</sup> The first study exploring and supporting the role of interatrial shunts in PAH was published by Austen et al almost 50 years ago.<sup>10</sup> This study is extraordinary, not only because it demonstrated that the surgical creation of an atrial septal defect (ASD) in the setting of experimental RV

Key Words—atrial septostomy, interventional cardiology, Potts anastomosis, right atrial pressure, transcatheter Potts shunt

Correspondence: sandovalzarate@prodigy.net.mx

Disclosures: The authors have nothing to disclose.

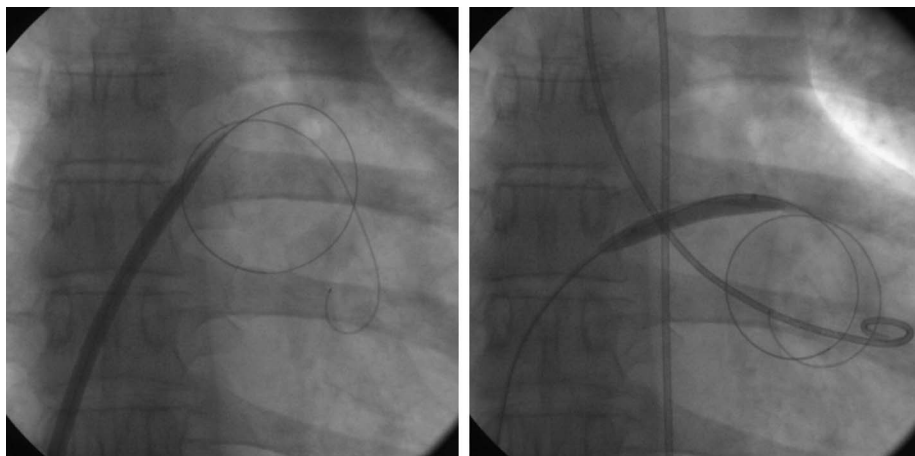


Figure 1: Balloon dilation atrial septostomy. After perforation of the septum with the Brockenbrough needle, a circular-end guidewire is positioned in the left atrium. An initial dilation of the atrial septum is done with the Inoue dilator (left panel), and concluded with balloons of different sizes (right panel) in a step-by-step manner.

hypertension provided hemodynamic benefit at rest and during exercise, but also because it described most of the knowledge we now possess regarding the physiological changes caused by atrial septostomy in the setting of PAH. In his original publication, Austen proposed that the surgical creation of an ASD should be performed for the management of patients with “primary” pulmonary hypertension (PPH).<sup>10</sup> Interestingly, this operation never took place in part because years later, nonsurgical creation of an ASD for the management of CHD (ie, transposition of the great arteries) was successfully achieved by Rashkind<sup>5</sup> and Park.<sup>6</sup>

Continuous improvements in transcatheter techniques to create an ASD became an attractive alternative in the setting of human PAH. In 1983, Rich and Lam<sup>11</sup> were the first to perform this intervention. The rationale was that clinical deterioration and death in PPH were associated with obstruction to systemic flow and dilation and failure of the RV, thus creation of an ASD in this context would allow a right-to-left shunt to increase systemic output and allow for decompression of the right chambers, alleviating RVF. Initial case series published in the early 1990s<sup>12–14</sup> appeared to confirm this hypothesis and showed promising hemodynamic benefits for PAH patients, albeit with a high procedure-related mortality. Hence, recommendations to minimize procedure-related mortality were made at the

World Symposium on PH in 1998,<sup>15,16</sup> and have remained since.

### Procedure

The technique of atrial septostomy has evolved over time and has undergone minor modifications by performing centers. At present, balloon dilation atrial septostomy (BDAS) is the preferred technique.<sup>14,17</sup> It involves a standard right and left heart catheterization; baseline right and left heart pressures are recorded simultaneously and cardiac output is calculated by Fick method. Following baseline hemodynamic assessment, standard trans-septal puncture is performed using a Brockenbrough needle and a Mullins-type dilator. In recent years, the use of intracardiac echocardiography has been advocated to acquire better visualization of the atrial septum to guide trans-septal puncture.<sup>18</sup> In addition, radiofrequency-assisted perforation of the atrial septum has been described as a safe and feasible alternative to conventional needle puncture.<sup>19</sup> Once access into the left atrium is gained, the septostomy orifice is sequentially dilated using noncompliant peripheral balloons in a carefully graded step-by-step manner, beginning with a 4 mm diameter balloon, followed by dilation with an 8 mm, 12 mm, and 16 mm balloon if needed (Figure 1). Between each step and after a 3-minute waiting period allowing hemodynamic stabilization, left ventricular end-diastolic pressure (LVEDP) and arterial oxygen

saturation ( $\text{SaO}_2$ ) are obtained. The final diameter of the ASD is reached on an individual basis when any of the following criteria are met: 1) LVEDP increase to  $\geq 18$  mm Hg; 2) decrease in  $\text{SaO}_2$  to 80% or below; or 3) a 10%  $\text{SaO}_2$  decrease from baseline. Post-procedure care requires a stay in the intensive care unit for at least 48 hours, where continuous supplementary oxygen is delivered and appropriate anticoagulation is started. Upon hospital discharge, all patients are followed as outpatients, with particular attention to maintaining effective oral anticoagulation and appropriate hemoglobin levels.<sup>14,17</sup>

### Worldwide Experience

Proper appreciation of the role of atrial septostomy in the management of PAH has been limited mainly by the lack of controlled clinical trials demonstrating its efficacy and safety. Most of our knowledge regarding the procedure comes from small series of patients or case reports. In addition, the relative success of current pharmacologic strategies, as well as the notion of a previously reported high procedure-related mortality<sup>12,13,20</sup> have prevented widespread use of this valuable intervention. Despite these limitations, experience with atrial septostomy has increased in the past few years.

In a recent worldwide experience review,<sup>21</sup> 372 procedures performed in 324 patients were identified; 304 had been reported in case series and another 20 as case reports. This experience is further enriched by the recent report of 85 procedures performed in 63 patients reported in 4 series<sup>22–25</sup> and 3 more reported as case reports,<sup>18,26,27</sup> showing similar results. These studies demonstrate that atrial septostomy has largely been performed in young people (mean age 31 years), mostly women (~70%), and in patients with idiopathic PAH (IPAH) in functional classes III and IV (~77%). In a significant proportion, BDAS has been performed in patients with refractory CHF and recurrent syncope despite maximal medical treatment. In this context, BDAS is the procedure of choice, and the size of the defect usually varies from 8 to 18 mm, with a mean value of approximately

Table 1. Hemodynamic effects of atrial septostomy according to baseline right atrial pressure

Variable	Baseline RAP <10 mm Hg (N=27)		P value	Baseline RAP 10-20 mm Hg (N=51)		P value	Baseline RAP >20 mm Hg (N=26)		P value
	Before	After		Before	After		Before	After	
Syncope (%)	65.2			26.2			12		
RVF (%)	26			33.3			64		
Both (RVF + syncope)	8.7%			40.5%			24%		
RAP, mm Hg	5.8 ± 1.96	5.48 ± 3.1	0.622	14.1 ± 3.2	11.4 ± 3.8	0.001	25.8 ± 4.9	19.2 ± 4.4	0.001
LAP, mm Hg	4.9 ± 2.47	6.5 ± 2.5	0.050	5.3 ± 3.6	7.9 ± 4.2	0.001	7.9 ± 3	10.4 ± 3.7	0.024
R-L atrial pressure, mm Hg	1.17 ± 3.2	-1.32 ± 3.2	0.023	8.4 ± 4.1	3.3 ± 5.5	0.001	17.3 ± 5	7.7 ± 5.3	0.001
Mean PAP, mm Hg	62.8 ± 17	64 ± 19.6	0.588	64.9 ± 16.7	65.6 ± 16.7	0.617	64.8 ± 23	69.9 ± 24.7	0.185
Cardiac index, L/min/m <sup>2</sup>	2.37 ± 0.61	2.80 ± 0.7	0.001	2.10 ± 0.70	2.7 ± 0.9	0.001	1.6 ± 0.5	2.2 ± 0.6	0.001
SaO <sub>2</sub> (%)	93.5 ± 4.1	87.2 ± 7.4	0.001	92.9 ± 4.1	82.8 ± 7.4	0.001	92.2 ± 4.5	78.3 ± 9.7	0.001
Procedure-related mortality 1 month	0/27 (0%)			2/51 (4%)			11/26 (42.3%)		

RAP=mean right atrial pressure; RVF=right ventricular failure; LAP=mean left atrial pressure; PAP=pulmonary artery pressure; R-L=right minus left atrial pressure.<sup>21</sup>

11 mm. A large majority of patients (~86%) survive the procedure, with 90% of patients describing improvement in symptoms and functional capacity. Furthermore, approximately 13% of patients received a lung transplant at some point after the procedure.<sup>21</sup>

Overall procedure-related mortality is 14%, with 8% occurring within the first 24 hours due to refractory hypoxemia and an additional 6% occurring within the first month post-intervention. Baseline right atrial pressure (RAP), in particular RAP >20 mm Hg, remains the most significant risk factor for procedure-related mortality.<sup>28</sup> Low SaO<sub>2</sub> following intervention, perhaps in relation to an oversized septostomy, has also been associated with higher risk of death.<sup>21</sup> Technical expertise and experience with the procedure also contribute to mortality, as reflected by lower mortality reported in recent series.<sup>22,23,29</sup>

The hemodynamic effects of an atrial septostomy depend highly on the baseline RAP. Table 1 shows how a higher baseline RAP will result in a more pronounced hemodynamic effect, particularly when RAP is >20 mm Hg (ie, severe RVF). However, as previously mentioned, patients with RAP >20 mm Hg will also have a significantly higher risk of death during the procedure as a result of refractory hypoxemia. Thus, it appears that the best risk-benefit ratio corresponds to the group with RAP between 10 and 20 mm Hg. Nevertheless, it should be noted that even when RAP is <10 mm Hg (predominantly patients presenting

with syncope), there is a significant increase in CI as well as an improvement in functional class, suggesting that septostomy at an earlier stage of disease could be beneficial.<sup>21</sup> It is also important to note that most of the hemodynamic variables reported have been obtained during the resting state and that the hemodynamic impact might be different and better during exercise, when the septostomy could be functioning as a “safety pop-off valve.” This concept of better function in patients having an ASD during exercise in the setting of RV hypertension was demonstrated by Austen many years ago,<sup>10</sup> and may in part explain the improvement in exercise tolerance reported by patients in some series.<sup>14,30-32</sup>

With regard to the long-term effects on RV function after septostomy, information is scarce, but there appears to be sustained improvement. Kerstein<sup>13</sup> and Law<sup>33</sup> have shown improvement in long-term hemodynamics: approximately 2 years after septostomy. Likewise, Espínola-Zavaleta<sup>34</sup> showed that, 3 to 6 months after septostomy, there was a decrease in right atrial area and in end-systolic and end-diastolic RV areas, a finding compatible with decompression of the right-sided chambers. In agreement with this decompression phenomenon and the relief of failure is the report from O’Byrne et al,<sup>35</sup> demonstrating a significant decrease in b-type natriuretic peptide (BNP) after septostomy. Atrial septostomy may also have additional beneficial effects on RV

function. Ciarka and coworkers<sup>36</sup> showed a significant decrease in muscle sympathetic nerve activity after the procedure; of interest, sympathetic overdrive in PAH may be one mechanism involved in RVF.<sup>37</sup>

Spontaneous closure of the septostomy is not an infrequent finding during follow-up. This situation can be overcome by repeating the procedure.<sup>14</sup> In addition, alternative interventions such as deployment of a fenestrated device (ie, Amplatzer septal occluder),<sup>38-42</sup> concomitant use of a butterfly stent (flared at both extremes),<sup>32,43,44</sup> and cryo-ablation of the septostomy borders<sup>18</sup> have been described. However, the safety and long-term efficacy of these additional interventions remains to be determined.

There is no definitive answer regarding the optimal size of the defect, and the size of the septostomy should be performed on an individual basis. One should aim to increase cardiac output and decompress the RV, but refractory hypoxemia should be avoided. Based on recent experimental data, it would appear that increasing cardiac output no more than 15% to 20% from baseline would provide the greatest benefits and results.<sup>45-47</sup>

Although atrial septostomy improves hemodynamic variables that correlate with clinical improvement and survival, true impact of septostomy on survival of patients with PAH is difficult to assess due to lack of controlled long-term studies (something that is also true for most of the current pharmacological



options). However, the survival rates for patients with long-term follow-up in different case series appear to be better when compared with either historical controls or predicted survival.<sup>13,22,29,32,33</sup> Unfortunately, during follow-up there is a significant drop of cumulative survival in time, reflecting the palliative nature of the procedure. In other words, atrial septostomy does not cure or reverse PAH and the beneficial effects of the procedure erode over time. The short- or median-term impact on survival, however, provides valuable time for the application of other noteworthy interventions (ie, PAH-specific drugs and/or transplantation).

In summary, based on the review of the worldwide collective experience, atrial septostomy stands as an additional strategy in the treatment of severe RVF from PAH. In the majority of cases, the procedure has been performed at an advanced stage of the disease in patients already burdened with a significantly higher risk of death; yet, despite progression of disease in these patients, BDAS frequently leads to clinical and hemodynamic improvement. Analysis of the worldwide clinical experience suggests that procedure-related mortality is decreasing. In this regard, the following guidelines are important: 1) do not perform septostomy in moribund patients (those with RAP >20 mm Hg); 2) always perform BDAS using a step-by-step approach; 3) employ constant monitoring of hemodynamic variables (RAP, LVEDP, CI, and SaO<sub>2</sub>); 4) limit the size of the defect to aim for a decrease in baseline SaO<sub>2</sub> of no more than 10% and an increase in baseline CI of no more than 15% to 20%; 5) BDAS should only be performed in centers widely experienced in both interventional cardiology and PH. The “ideal” candidate for the procedure remains a patient in functional class III, with RAP between 10 and 18 mm Hg and a baseline SaO<sub>2</sub> >90%, with history of syncope or persistent RVF despite maximal medical therapy as part of a goal-oriented strategy.<sup>3</sup> The procedure may also be considered either as a bridge to lung transplant or as the sole treatment modality when other therapeutic options are not available.

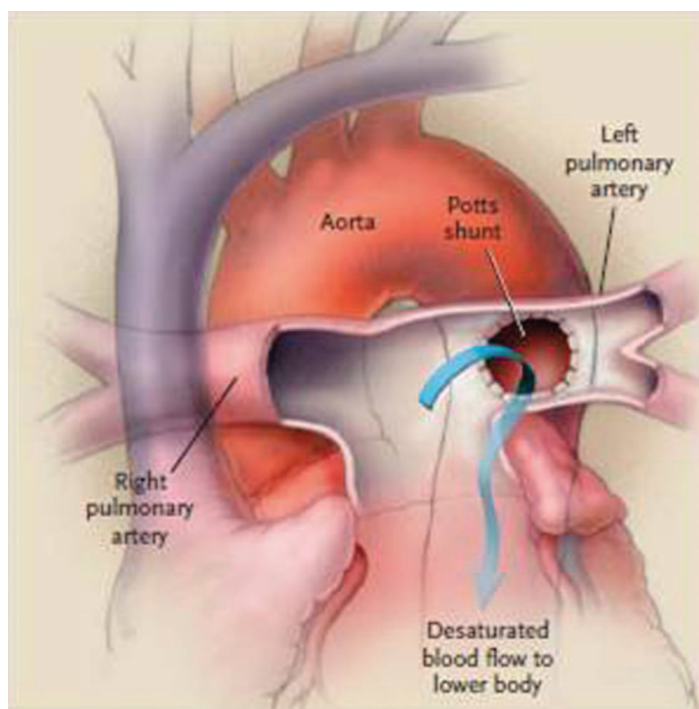


Figure 2: Schematic representation of the Potts anastomosis. The procedure consists of the surgical creation of a side-by-side anastomosis between the left pulmonary artery and the descending aorta. From Blanc J, Vouhé P, Bonnet D. Potts shunt in patients with pulmonary hypertension. *N Engl J Med*. 2004;350(6):623. Reprinted with permission from Massachusetts Medical Society.

### POTTS SHUNT

Potts' aortopulmonary anastomosis was originally intended as a form of palliative treatment for some CHD with diminished pulmonary blood flow.<sup>48</sup> The procedure, which employs a side-by-side anastomosis between the left pulmonary artery and the descending aorta, has been recently reexamined in the management of refractory PAH<sup>49,50</sup> as a surgical/interventional alternative to atrial septostomy. It shares the same concept and rationale: that is, to produce a right-to-left shunt to increase systemic output, but at a post-tricuspid level, similar to that observed in patients with patent ductus arteriosus (PDA) and PH who survive longer and have less right heart failure than patients with IPAH.<sup>8,9</sup> In theory, the main advantage of a Potts shunt over an atrial septostomy is that it creates a permanent postcardiac right-to-left shunt that does not lead to arterial oxygen desaturation in the upper part of the body, including the brain and the coronary circulation.<sup>50-52</sup>

Since the original description by Blanc and coworkers<sup>49</sup> of successful application of this surgical procedure in 2 boys with suprasystemic PH after an arterial switch

for transposition of the great arteries (Figure 2), experience and interest have rapidly expanded.<sup>50-57</sup> The surgical procedure is performed under general anesthesia, usually via a left thoracotomy without cardiopulmonary bypass, and the size of the shunt (which remains controversial) is set at ~9 mm.

Until now, this surgical approach has been performed mostly in children with refractory PAH at an advanced stage of disease where Potts anastomosis may be considered a lifesaving procedure. This procedure often results in significant improvement in functional class, exercise tolerance, and reduced levels of natriuretic peptides in survivors.<sup>49-57</sup> However, there is also an inherent risk of mortality during or after this surgical procedure in this very sick PAH population. Also, adults with PAH and severe RVF undergoing this intervention might have a different postoperative prognosis and higher perioperative mortality.

### TRANSCATHETER POTTS SHUNT

To bypass the potential risks associated with surgery and after demonstrating its feasibility in animal models,<sup>58</sup> an inno-

vative technique using a transcatheter approach to create a Potts shunt (TPS) has been recently described in humans with PAH.<sup>59</sup> In this report, 4 patients with severe PAH underwent TPS. Under general anesthesia, vascular perforation was guided by fluoroscopy, and the shunt was created via placement of an iCAST 7x22 mm covered stent (Atrium Medical, Hudson, NH, USA) between the left pulmonary artery and the descending aorta. Although considered technically successful in 3 cases, 1 patient died during the procedure as a result of uncontrolled hemothorax, and another died just a few days later as result of ventilation-associated pneumonia. The remaining 2 patients showed significant symptomatic improvement and had no complications after 4 and 10 months during follow-up.

Baruteau and coworkers have recently published a compendium of their experience with both surgical anastomosis and TPS in the management of PAH.<sup>51</sup> Their pooled data on 24 children (aged 1.5–17 years) who underwent Potts shunt (19 surgical, 5 TPS) for drug-refractory PAH demonstrated severe postoperative complications occurring in 6 patients (25% of the surgical group), including 3 early deaths (12.5%) due to low cardiac output. After a median follow-up of 2.1 years (range, 3 months to 14.3 years), 6-minute walk and functional class were improved in the remaining 21 survivors (World Health Organization functional class I or II). None of the patients experienced syncope or worsening RVF. BNP/NT-proBNP levels returned to normal in all patients. The authors concluded that creation of a palliative Potts shunt prolonged survival and dramatically and consistently improved functional class in children with severe, drug-refractory PAH.

Bleeding (massive hemothorax) is the most feared complication of TPS. In this regard, computed tomography of the thorax prior to the procedure could help select the ideal candidate for surgery.<sup>60</sup> In this study, the authors described 2 types of relationships between left lower pulmonary artery and descending aorta; in type 1, there is practically no distance between the vessels, and in type 2 the

gap between the structures is greater, thus increasing the risk of bleeding. In theory, type 1 patients represent the ideal candidates for TPS anastomosis. A radiofrequency-assisted perforation approach is yet another refinement to try to improve the safety and efficacy of TPS creation.<sup>61</sup>

The concept of the potential benefit of this type of pulmonary-to-systemic shunt in the setting of PH has been applied to the pediatric population by creation of a “functional” Potts by stenting the ductus arteriosus in newborns and infants with suprasystemic PH of various etiologies.<sup>62,63</sup>

Although creating a post-tricuspid shunt would be intuitive based on data from Eisenmenger patients with PDA, it remains to be determined whether a post-tricuspid defect will prove equal to or superior to atrial septostomy. Apart from the expected reduction in RV afterload, there are several issues to consider when bypassing the pulmonary artery flow to the descending aorta. The most important is the potential equalization of systemic and pulmonary pressures, limiting the ability to further offload the RV and the concern of a left-to-right shunt during exercise and/or the development of systemic hypertension with aging. To address this potential problem, a unidirectional valved conduit for surgical Potts shunt has been developed and tested in an experimental animal model of PAH.<sup>58</sup>

In sum, it appears that Potts anastomosis (surgical or interventional) is indeed an innovative approach for management of PAH and an alternative to atrial septostomy. However, more experience and refinement of the technique is needed both to reduce the risks associated with the surgical approach and to establish TPS as an accepted therapeutic modality for advanced PAH.

## CONCLUSION

Despite advances in pharmacologic treatment, PAH remains a fatal disease. BDAS and the recently adopted surgical/interventional Potts anastomosis stand as therapeutic alternatives in selected patients with refractory RVF from PAH. These interventions may improve quality of life and prolong survival in this popu-

lation. Substantial experience with these procedures has been limited by the relative success of current pharmacologic strategies and the lack of significant expertise to master the techniques; however, these interventions should be available and performed in centers experienced in both interventional cardiology and PH. The optimal timing of when to perform either remains a challenge, but we should not be delayed to the point of being contraindicated or ineffective.

## References

1. D'Alonzo GE, Barst RJ, Ayres SM, et al. Survival in patients with primary pulmonary hypertension. Results from a national prospective registry. *Ann Intern Med.* 1991;115(5):343-349.
2. Sandoval J, Bauerle O, Palomar A, et al. Survival in primary pulmonary hypertension. Validation of a prognostic equation. *Circulation.* 1994;89(4):1733-1744.
3. Galie N, Corris PA, Frost A, et al. Updated treatment algorithm of pulmonary arterial hypertension. *J Am Coll Cardiol.* 2013;62(25 Suppl): D60-D72.
4. Humbert M, Sitbon O, Chaouat A, et al. Survival in patients with idiopathic, familial, and anorexigen-associated pulmonary arterial hypertension in the modern management era. *Circulation.* 2010;122(2):156-163.
5. Rashkind WJ, Miller WW. Creation of an atrial septal defect without thoracotomy. A palliative approach to complete transposition of the great arteries. *JAMA.* 1966;196(11):991-992.
6. Park SC, Neches WH, Mullins CE, et al. Blade atrial septostomy: collaborative study. *Circulation.* 1982;66(2):258-266.
7. Rozkovec A, Montanes P, Oakley CM. Factors that influence the outcome of primary pulmonary hypertension. *Br Heart J.* 1986;55(5): 449-458.
8. Hopkins WE. The remarkable right ventricle of patients with Eisenmenger syndrome. *Coron Artery Dis.* 2005;16(1):19-25.
9. Hopkins WE, Ochoa LL, Richardson GW, Trulock EP. Comparison of the hemodynamics and survival of adults with severe primary pulmonary hypertension or Eisenmenger syndrome. *J Heart Lung Transplant.* 1996;15(1 Pt 1):100-105.
10. Austen WG, Morrow AG, Berry WB. Experimental studies of the surgical treatment of primary pulmonary hypertension. *J Thorac Cardiovasc Surg.* 1964;48:448-455.
11. Rich S, Lam W. Atrial septostomy as palliative therapy for refractory primary pulmonary hypertension. *Am J Cardiol.* 1983;51(9):1560-1561.
12. Nihill MR, O'Laughlin MP, Mullins CE. Effects of atrial septostomy in patients with terminal cor pulmonale due to pulmonary vascular disease. *Cathet Cardiovasc Diagn.* 1991;24(3): 166-172.
13. Kerstein D, Levy PS, Hsu DT, Hordof AJ, Gersony WM, Barst RJ. Blade balloon atrial septostomy in patients with severe primary pulmonary

- hypertension. *Circulation*. 1995;91(7):2028-2035.
14. Sandoval J, Gaspar J, Pulido T, et al. Graded balloon dilation atrial septostomy in severe primary pulmonary hypertension. A therapeutic alternative for patients nonresponsive to vasodilator treatment. *J Am Coll Cardiol*. 1998;32(2):297-304.
15. Rich S, Rubin LJ, Abenhail L, et al. Executive summary from the World Symposium on Primary Pulmonary Hypertension, Evian, France; September 6-10, 1998. Geneva, Switzerland: World Health Organization, 1998.
16. Sandoval J, Rothman A, Pulido T. Atrial septostomy for pulmonary hypertension. *Clin Chest Med*. 2001;22(3):547-560.
17. Sandoval J, Gaspar J. Atrial septostomy and other interventional procedures. In: Peacock AJ, Naeije R, Rubin LJ, eds. *Pulmonary circulation. Diseases and their treatment*. 3rd ed. London: Hodder Arnold Ltd; 2011:391-404.
18. Guerrero M, Cajigas H, Awdish R, Greenbaum A, Khandelwal A, Sandoval J. First-in-man experience with cryoplasty during graded balloon atrial septostomy to reduce spontaneous closure in a patient with severe pulmonary arterial hypertension. *EuroIntervention*. 2014;9(10):1235-1236.
19. Baglini R. Atrial septostomy in patients with end-stage pulmonary hypertension. No more needles but wires, energy and close anatomical definition. *J Interv Cardiol*. 2013;26(1):62-68.
20. Rich S, Dodin E, McLaughlin VV. Usefulness of atrial septostomy as a treatment for primary pulmonary hypertension and guidelines for its application. *Am J Cardiol*. 1997;80(3):369-371.
21. Sandoval J, Torbicki A. Atrial septostomy. In: Voelkel NF, Schranz D, eds. *Right ventricle in health and disease*. New York, NY: Humana Press, Springer Science + Business Media; 2015: 419-437.
22. Chiu JS, Zuckerman WA, Turner ME, et al. Balloon atrial septostomy in pulmonary arterial hypertension: effect on survival and associated outcomes. *J Heart Lung Transplant*. 2015;34(3):376-380.
23. Kuhn BT, Javed U, Armstrong EJ, et al. Balloon dilation atrial septostomy for advanced pulmonary hypertension in patients on prostanoïd therapy. *Catheter Cardiovasc Interv*. 2015;85(6):1066-1072.
24. Velázquez Martín M, Albarrán González-Trevilla A, Jiménez López-Guarch C, García Tejada J, Martín Asenjo R, Escibano Subías P. Use of atrial septostomy to treat severe pulmonary arterial hypertension in adults. *Rev Esp Cardiol (Engl Ed)*. 2016;69(1):78-81.
25. Pan X, Wang C, Zhang Y, et al. [Short-term efficacy of atrial septostomy in the treatment of idiopathic pulmonary arterial hypertension patients complicating with right heart failure]. *Zhonghua Xin Xue Guan Bing Za Zhi*. 2015;43(4):319-322.
26. Flores S, Daily J, Pratap JN, Cash MC, Hirsch R. Management of a child with pulmonary arterial hypertension presenting with systemic hypertension. *Cardiol Young*. 2016;26(2):378-381.
27. Latus H, Apitz C, Schmidt D, et al. Potts shunt and atrial septostomy in pulmonary hypertension caused by left ventricular disease. *Ann Thorac Surg*. 2013;96(1):317-319.
28. Klepetko W, Mayer E, Sandoval J, et al. Interventional and surgical modalities of treatment for pulmonary arterial hypertension. *J Am Coll Cardiol*. 2004;43(12 Suppl S):73S-80S.
29. Sandoval J, Gaspar J, Peña H, et al. Effect of atrial septostomy on the survival of patients with severe pulmonary arterial hypertension. *Eur Respir J*. 2011;38(6):1343-1348.
30. Allcock RJ, O'Sullivan JJ, Corris PA. Atrial septostomy for pulmonary hypertension. *Heart*. 2003;89(11):1344-1347.
31. Vachieri JL, Stoupe E, Boonstra A, Naeije R. Balloon atrial septostomy for pulmonary hypertension in the prostacyclin era. *Am J Respir Crit Care Med*. 2003;167:A692.
32. Troost E, Delcroix M, Gewillig M, Van Deyk K, Budts W. A modified technique of stent fenestration of the interatrial septum improves patients with pulmonary hypertension. *Catheter Cardiovasc Interv*. 2009;73(2):173-179.
33. Law MA, Grifka RG, Mullins CE, Nihill MR. Atrial septostomy improves survival in select patients with pulmonary hypertension. *Am Heart J*. 2007;153(5):779-784.
34. Espinola-Zavaleta N, Vargas-Barrón J, Tazar JI, et al. Echocardiographic evaluation of patients with primary pulmonary hypertension before and after atrial septostomy. *Echocardiography*. 1999;16(7 Pt 1):625-634.
35. O'Byrne ML, Rosenzweig ES, Barst RJ. The effect of atrial septostomy on the concentration of brain-type natriuretic peptide in patients with idiopathic pulmonary arterial hypertension. *Cardiol Young*. 2007;17(5):557-559.
36. Ciarka A, Vachieri JL, Houssière A, et al. Atrial septostomy decreases sympathetic overactivity in pulmonary arterial hypertension. *Chest*. 2007;131(6):1831-1837.
37. Velez-Roa S, Ciarka A, Najem B, Vachieri JL, Naeije R, van de Borne P. Increased sympathetic nerve activity in pulmonary artery hypertension. *Circulation*. 2004;110(10):1308-1312.
38. Micheletti A, Hislop AA, Lammers A, et al. Role of atrial septostomy in the treatment of children with pulmonary arterial hypertension. *Heart*. 2006;92(7):969-972.
39. Fraisse A, Chetaille P, Amin Z, Rouault F, Humbert M. Use of Amplatzer fenestrated atrial septal defect device in a child with familial pulmonary hypertension. *Pediatr Cardiol*. 2006;27(6):759-762.
40. O'Loughlin AJ, Keogh A, Muller DW. Insertion of a fenestrated Amplatzer atrial septostomy device for severe pulmonary hypertension. *Heart Lung Circ*. 2006;15(4):275-277.
41. Althoff TF, Knebel F, Panda A, et al. Long-term follow-up of a fenestrated Amplatzer atrial septal occluder in pulmonary arterial hypertension. *Chest*. 2008;133(1):283-285.
42. Baglini R, Scardulla C. Reduction of a previous atrial septostomy in a patient with end-stage pulmonary hypertension by a manually fenestrated device. *Cardiovasc Revasc Med*. 2010;11(4):264.e9-11.
43. Prieto LR, Latson LA, Jennings C. Atrial septostomy using a butterfly stent in a patient with severe pulmonary arterial hypertension. *Catheter Cardiovasc Interv*. 2006;68(4):642-647.
44. Roy AK, Gaïne SP, Walsh KP. Percutaneous atrial septostomy with modified butterfly stent and intracardiac echocardiographic guidance in a patient with syncope and refractory pulmonary arterial hypertension. *Heart Lung Circ*. 2013;22(8):668-671.
45. Zierer A, Melby SJ, Voeller RK, Moon MR. Interatrial shunt for chronic pulmonary hypertension: differential impact of low-flow vs. high-flow shunting. *Am J Physiol Heart Circ Physiol*. 2009;296(3):H639-H644.
46. Weimar T, Watanabe Y, Kazui T, et al. Impact of differential right-to-left shunting on systemic perfusion in pulmonary arterial hypertension. *Catheter Cardiovasc Interv*. 2013;81(5):888-895.
47. Koeken Y, Kuijpers NH, Lumens J, Arts T, Delhaas T. Atrial septostomy benefits severe pulmonary hypertension patients by increase of left ventricular preload reserve. *Am J Physiol Heart Circ Physiol*. 2012;302(12):H2654-H2662.
48. Potts WJ, Smith S, Gibson S. Anastomosis of the aorta to a pulmonary artery; certain types in congenital heart disease. *J Am Med Assoc*. 1946;132(11):627-631.
49. Blanc J, Vouhé P, Bonnet D. Potts shunt in patients with pulmonary hypertension. *N Engl J Med*. 2004;350(6):623.
50. Baruteau AE, Serraf A, Lévy M, et al. Potts shunt in children with idiopathic pulmonary arterial hypertension: long-term results. *Ann Thorac Surg*. 2012;94(3):817-824.
51. Baruteau AE, Belli E, Boudjemline Y, et al. Palliative Potts shunt for the treatment of children with drug-refractory pulmonary arterial hypertension: updated data from the first 24 patients. *Eur J Cardiothorac Surg*. 2015;47(3):e105-e110.
52. Grady RM, Egtesady P. Potts Shunt and Pediatric Pulmonary Hypertension: What We Have Learned. *Ann Thorac Surg*. 2016;101(4):1539-1543.
53. Kim SH, Jang WS, Lim HG, Kim YJ. Potts shunt in patients with primary pulmonary hypertension. *Korean J Thorac Cardiovasc Surg*. 2015;48(1):52-54.
54. Schranz D, Kerst G, Menges T, et al. Transcatheter creation of a reverse Potts shunt in a patient with severe pulmonary arterial hypertension associated with Moyamoya syndrome. *EuroIntervention*. 2015;11(1):121.
55. Fiszer R, Karwot B, Chodór B, et al. Potts' shunt in a child with idiopathic pulmonary arterial hypertension - one-and-a-half year observation. *Kardiolog Torakochirurgia Pol*. 2015;12(2):170-172.
56. Żuk M, Mazurkiewicz-Antoń K, Mirecka-Rola A, Kawalec W. Potts shunt in child with suprasystemic pulmonary arterial hypertension. *Kardiolog Pol*. 2015;73(3):221.
57. Keogh AM, Nicholls M, Shaw M, et al. Modified Potts shunt in an adult with pulmonary arterial hypertension and recurrent syncope - three-year follow-up. *Int J Cardiol*. 2015;182:36-37.
58. Bui MT, Grollmus O, Ly M, et al. Surgical palliation of primary pulmonary arterial hypertension by a unidirectional valved Potts anastomosis in an animal model. *J Thorac Cardiovasc Surg*. 2011;142(5):1223-1228.
59. Esch JJ, Shah PB, Cockrill BA, et al. Transcatheter Potts shunt creation in patients with



- severe pulmonary arterial hypertension: initial clinical experience. *J Heart Lung Transplant*. 2013; 32(4):381-387.
60. Guo K, Langleben D, Afilalo J, et al. Anatomical considerations for the development of a new transcatheter aortopulmonary shunt device in patients with severe pulmonary arterial hypertension. *Pulm Circ*. 2013;3(3):639-646.
61. Sayadpour Zanjani K. Radiofrequency perforation may increase the safety of transcatheter Potts shunt creation. *J Heart Lung Transplant*. 2013; 32(9):938.
62. Latus H, Apitz C, Moysich A, et al. Creation of a functional Potts shunt by stenting the persistent arterial duct in newborns and infants with suprasystemic pulmonary hypertension of various etiologies. *J Heart Lung Transplant*. 2014; 33(5):542-546.
63. Boudjemline Y, Patel M, Malekzadeh-Milani S, Szezepanski I, Lévy M, Bonnet D. Patent ductus arteriosus stenting (transcatheter Potts shunt) for palliation of suprasystemic pulmonary arterial hypertension: a case series. *Circ Cardiovasc Interv*. 2013;6(2):e18-e20.
64. Sandoval J, Moraca RJ, Torbicki A. Interventional procedures in PAH. In: Benza R, Corris P, Park M, Uber P; eds. *Pulmonary hypertension and right heart failure*. ISHLT Monograph Series. Birmingham, AL: UAB Printing, University of Alabama at Birmingham; 2015.