Pulmonary Artery Filling Defects: Are They All the Same?

Section Editor
Deborah J. Levine, MD

Nadine Al-Naamani, MD
Tufts Medical Center
Boston, MA
Richard N. Channick, MD
Massachusetts General Hospital
Boston, MA
Ioana R. Preston, MD
Tufts Medical Center
Boston, MA

Section editor's note: The diagnostic evaluation of pulmonary hypertension (PH) is an extensive, yet specific, process. Each individual study is significant, but it is truly the insightful analysis of the combination of studies that assists us most in making the correct diagnosis. In this issue's PH Grand Rounds, we congratulate Dr Al-Naamani and her colleagues for reminding us to consider a more in-depth examination of the data prior to making what seems to be an obvious diagnosis. This case not only imparts valuable information on this particular diagnosis, it also demonstrates how this type of thought process is vital to both the diagnosis and therapy for our patients.

Presentation:
A 62-year-old man with a known history of Eisenmenger's syndrome and pulmonary arterial hypertension (PAH) secondary to congenital heart disease (CHD), status post atrial septal defect (ASD) closure, and paroxysmal atrial fibrillation on warfarin presented to a local hospital with 2 weeks of worsening dyspnea on exertion to a New York Heart Association functional class (NYHA FC) 3 and intermittent palpitations. His symptoms had been progressive and were occasionally associated with lightheadedness, but no syncope. His past medical history was remarkable for an ASD closure at the age of 40, and the diagnosis of PAH with NYHA FC 2 at the age of 57, when it was also determined that the ASD closure had opened. During his evaluation for PAH, he had undergone a chest x-ray, a ventilation/perfusion (V/Q) scan (Figure 1A), and a right heart catheterization (Table 1). He was treated with sildenafil and later macitentan was added (via a clinical trial), but he had stopped both drugs approximately 6 months prior due to financial reasons and side effects. At the time of current presentation, the patient was treated with warfarin and sotalol. He was found to be hypoxic and in atrial fibrillation, with heart rate ranging from 110 to 120 beats per minute with a stable blood pressure. He underwent a CT angiogram of the chest (CTPA), which was concerning for bilateral chronic pulmonary emboli with significantly enlarged pulmonary arteries. He was transferred to our medical center for further workup and evaluation.

Key Words—atrial septal defect, congenital heart disease, dyspnea, pulmonary arterial hypertension, pulmonary artery aneurysm
Correspondence: ipreston@tuftsmedicalcenter.org

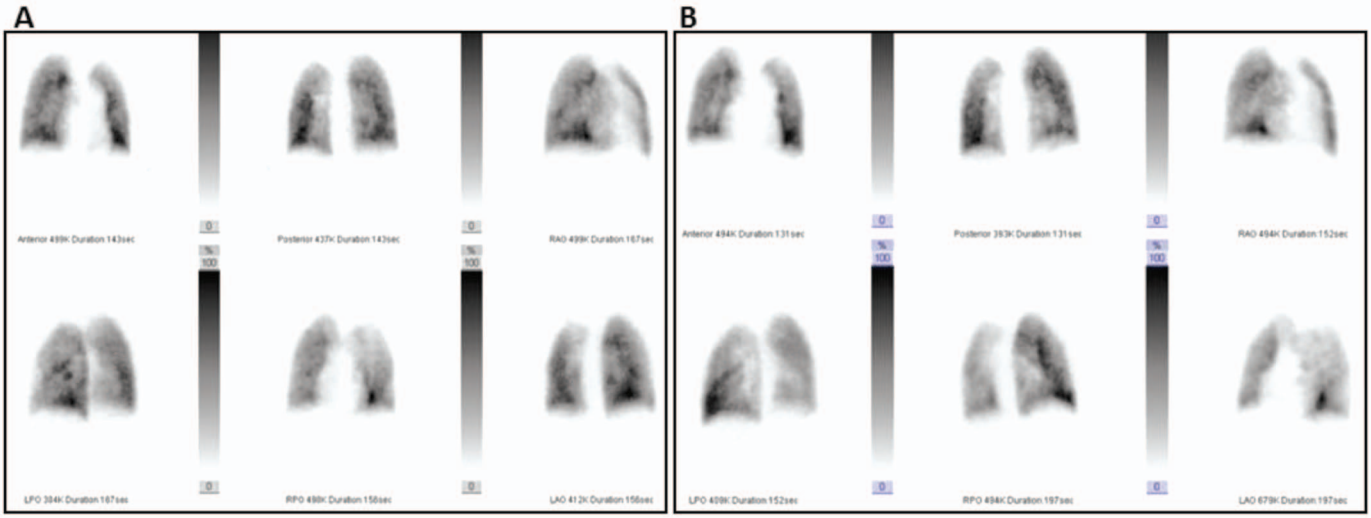

Figure 1: Lung perfusion scans at initial presentation for evaluation of PAH (A) and at current presentation (B)

Downloaded from https://prime-pdf-watermark.prime-prod.pubfactory.com/ at 2025-06-24 via free access

Table 1. Right heart catheterizations

	Initial	Current
Right atrial pressure, mm Hg	12/9 (7)	26/22 (18)
Right atrial oxygen saturation, %	66	56
Right ventricular pressure, mm Hg	91/4 (11)	73/15 (34)
Pulmonary artery pressure, mm Hg	92/41 (58)	75/43 (54)
Pulmonary artery oxygen saturation, %	65	59
Pulmonary artery wedge pressure, mm Hg	14/14 (11)	23/22 (18)
Cardiac output, L/min (thermodilution)	6.9	4.5
Cardiac index, L/min/m^2	3.5	2.3
Pulmonary vascular resistance, Wood units	6.8	8.0

Assessment:
His examination was remarkable for tachycardia with an irregular heart rhythm, a parasternal heave, and a holosystolic murmur at the left parasternal border. He did not have any evidence of jugular vein distension or lower extremity edema, and his examination was otherwise unremarkable. His blood work was significant for an international normalized ratio (INR) of 2.66, a brain natriuretic peptide (BNP) of 79 pg/mL, and a troponin I of <0.01 ng/mL. He had a lower extremity venous Doppler which showed no evidence of lower extremity venous thrombosis. His ECG showed atrial fibrillation at a rate of 112 beats per minute, right axis deviation with a right bundle branch block, and a left posterior fascicular block. An echocardiogram showed increased left ventricular (LV) wall thickness with mildly reduced LV systolic function (ejection fraction 40%), flattened septum consistent with right ventricular (RV) pressure or volume overload, bi-atrial dilatation with no evidence of intra-atrial shunt, and a severely dilated RV with severely reduced RV systolic function. Right heart catheterization was performed (Table 1). CTPA showed severe dilatation of the pulmonary arteries with nonocclusive, mural thrombi in the large pulmonary arteries (Figure 2A and B). V/Q lung scan showed diffuse heterogeneous nonsegmental perfusion defects in the lungs bilaterally without significant changes from baseline scan and consistent with underlying PAH (Figure 1B).

Diagnosis:
The patient was diagnosed with decompensated right heart failure due to

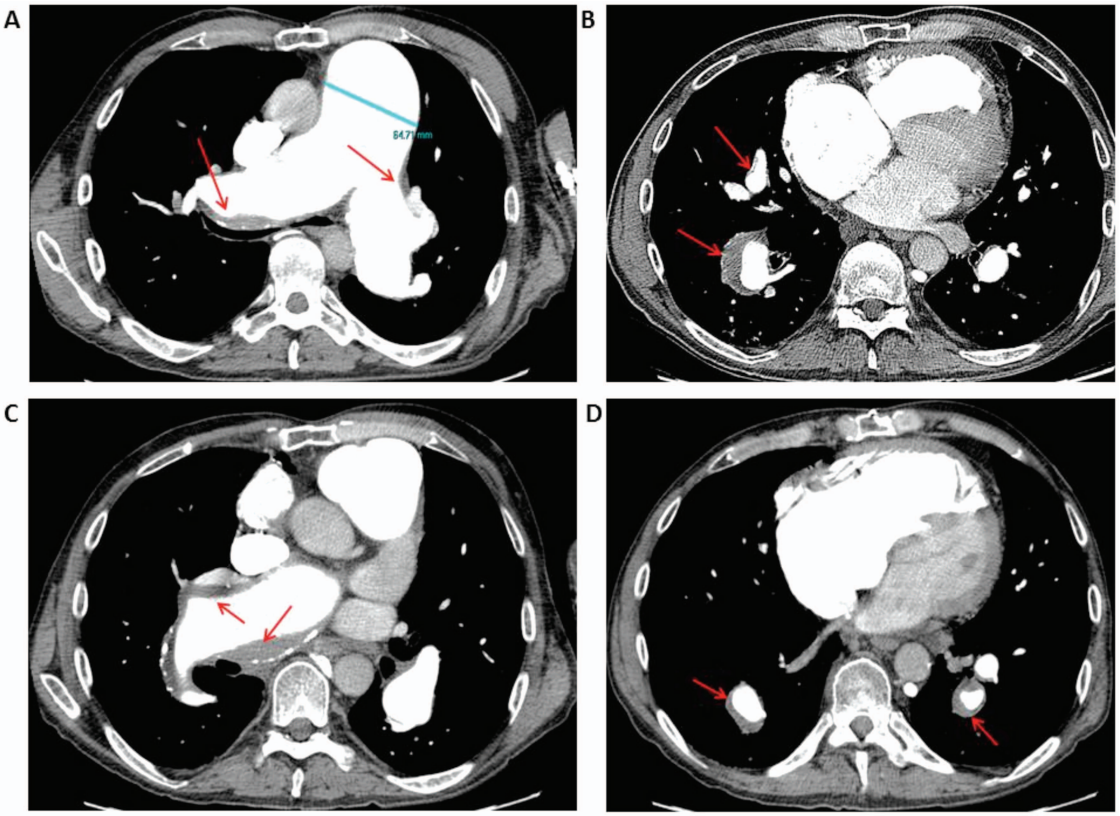

Figure 2: A. CTPA representative section demonstrating dilated ectatic pulmonary artery trunk measuring 64.7 mm (blue line) and nonocclusive intraluminal thrombi in the right pulmonary artery and the main pulmonary trunk (red arrows). B-D. Representative sections of the CTPA showing nonocclusive intraluminal thrombi in the right and left pulmonary artery branches (red arrows)

Downloaded from https://prime-pdf-watermark.prime-prod.pubfactory.com/ at 2025-06-24 via free access

untreated PAH. Imaging studies were evaluated at a chronic thromboembolic pulmonary hypertension (CTEPH) surgical center, and there was agreement with the diagnosis of PAH with secondary "lining" thrombus within the aneurysmal pulmonary arteries. Intravenous epoprostenol was initiated at a dose of 2 ng/kg/min, and it was titrated up by 2 ng/kg/min as tolerated. The patient was discharged from the hospital after placement of a single lumen Hickman on 12 ng/kg/min of epoprostenol, sotalol and warfarin. In our case, the chronicity of PAH along with review of the radiologic studies showing laminar organized thrombi favored a diagnosis of PAH with associated pulmonary artery aneurysm (PAA) and intramural thrombi. On follow-up in clinic 4 weeks post-hospital discharge, the patient reported significant improvement overall. His breathing had returned to baseline NYHA FC 2 without palpitations or syncope.

Discussion: Review of the Literature

PAA, characterized by enlargement of the pulmonary artery or its branches, is a rare condition that is most commonly associated with PAH or CHD.[1-4] PAA is not infrequently complicated by intramural thrombi and/or pulmonary artery dissection.[3] Most often, symptoms attributed to PAA are nonspecific and diagnosis is made by noninvasive imaging (chest roentgenogram, computerized tomography [CT], or magnetic resonance imaging [MRI]). The distinction between in situ thrombosis of the ectatic pulmonary arteries in the setting of PAH and CTEPH is of paramount importance given the significant therapeutic implications. We present a case that illustrates the difficulty of differentiation between these 2 conditions.

Specifically, the combination of a "low probability" V/Q scan and central eccentric mural thrombi supported the conclusion that the patient did not have CTEPH. In addition, if there is consideration that the thrombi are hemodynamically relevant, right heart catheterization and measurement of the pressure gradient across these lesions may be informative. In PAH with secondary central thrombi, there should be no pressure gradient from the proximal to distal branches (Channick RN, personal communication, September 2014).

There are several case reports in the literature about PAA in association with PAH; however, the management of this condition remains controversial.[1-6] PAA can be complicated by hemoptysis, pulmonary artery dissection and/or rupture, intramural thrombi, or mechanical compression of adjacent structures—namely the coronary arteries, main bronchi, or the superior vena cava.[3] Although anticoagulation would be logical to decrease the incidence of thrombi in the setting of PAA, the decision is often difficult because PAAs are inherently at increased risk of bleeding.[2]

In patients with long-standing PAH, especially when associated with CHD, chest imaging can reveal the presence of PAA. Given the clinical, prognostic, and therapeutic implications, it is important for physicians who care for such patients to distinguish between PAA associated with intramural thrombi and CTEPH.

References

1. Barbour DJ, Roberts WC. Aneurysm of the pulmonary trunk unassociated with intracardiac or great vessel left-to-right shunting. *Am J Cardiol*. 1987;59(1):192-194.
2. Broberg C, Ujita M, Babu-Narayan S, et al. Massive pulmonary artery thrombosis with haemoptysis in adults with Eisenmenger's syndrome: a clinical dilemma. *Heart*. 2004;90(11):e63.
3. Bartter T, Irwin RS, Nash G. Aneurysms of the pulmonary arteries. *Chest*. 1988;94(5):1065-1075.
4. Moser KM, Fedullo PF, Finkbeiner WE, Golden J. Do patients with pulmonary hypertension develop extensive central thrombi? *Circulation*. 1995;91(3):741-745.
5. Agarwal PP, Wolfsohn AL, Matzinger FR, Seely JM, Peterson RA, Dennie C. In situ central pulmonary artery thrombosis in primary pulmonary hypertension. *Acta Radiol*. 2005;46(7):696-700.
6. Della Coletta JA, Tanni SE, Coelho LS, Cataneo DC, Ribeiro SM, Godoy I. Pulmonary artery aneurysm complicated by mural thrombus: a case report. *Am J Med Sci*. 2008;336(1):69.

Downloaded from https://prime-pdf-watermark.prime-prod.pubfactory.com/ at 2025-06-24 via free access